

# Pediatric Reconstruction of a Pathologic Defect with Dental Implants, A Case Review After 10 Years

George Vattes, DDS Andrew Marks, DDS, FACS Keith Murtagh, DDS  
Brookdale University Hospital Medical Center, One Brooklyn Health

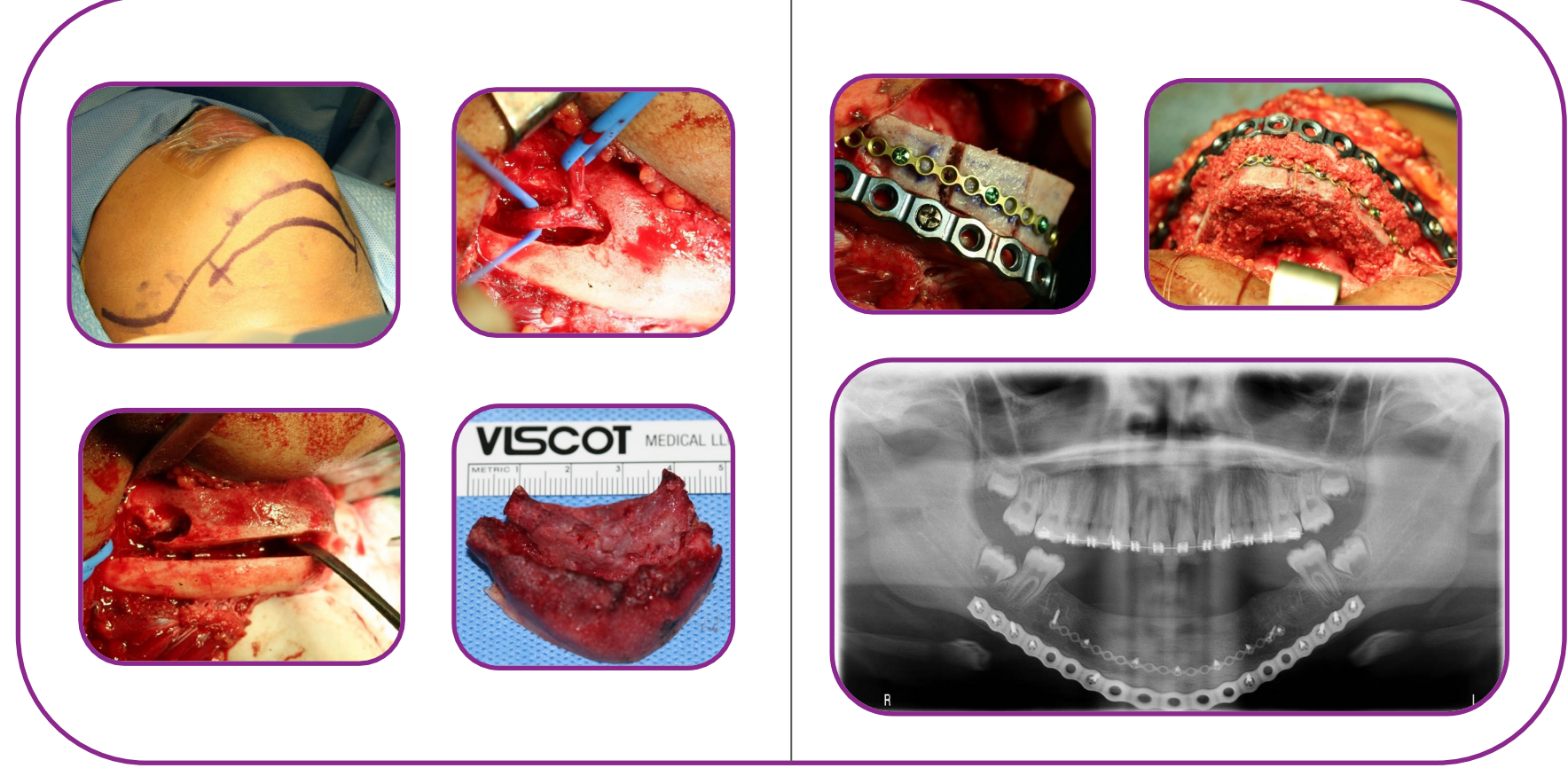


## INTRODUCTION

Ameloblastoma is an epithelial odontogenic tumor demonstrating locally aggressive and destructive behavior with a high likeness for recurrence. This neoplasm of the jaws represents 1% of the oral tumors occurring mostly in the third decade of life. Treatment and prognosis are dependant on the variant of the ameloblastoma of which there are three: multicystic, unicystic, and peripheral.

Surgical management of this pathologic entity has been the source of much controversy over the years, with rationale existing for both "conservative" surgical management, and resection. While numerous studies support surgical options as marginal resection or peripheral osteotomy for the initial treatment of most ameloblastomas, it is argued complete resection is the only curative therapy for this potentially lethal neoplasm. Regardless, reconstruction and restoration of function with dental implants provides an esthetic achievable goal.

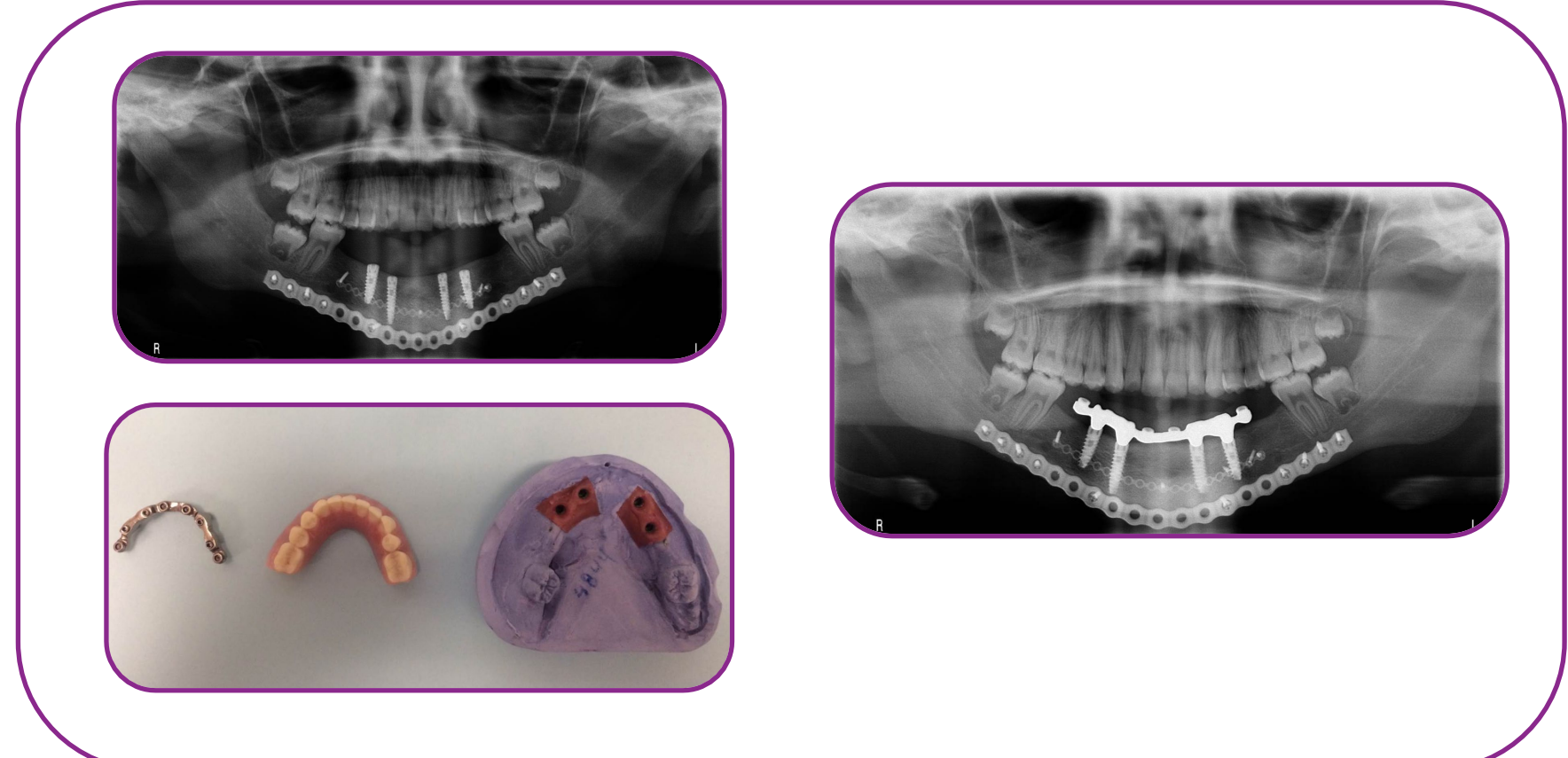
## PROCEDURE



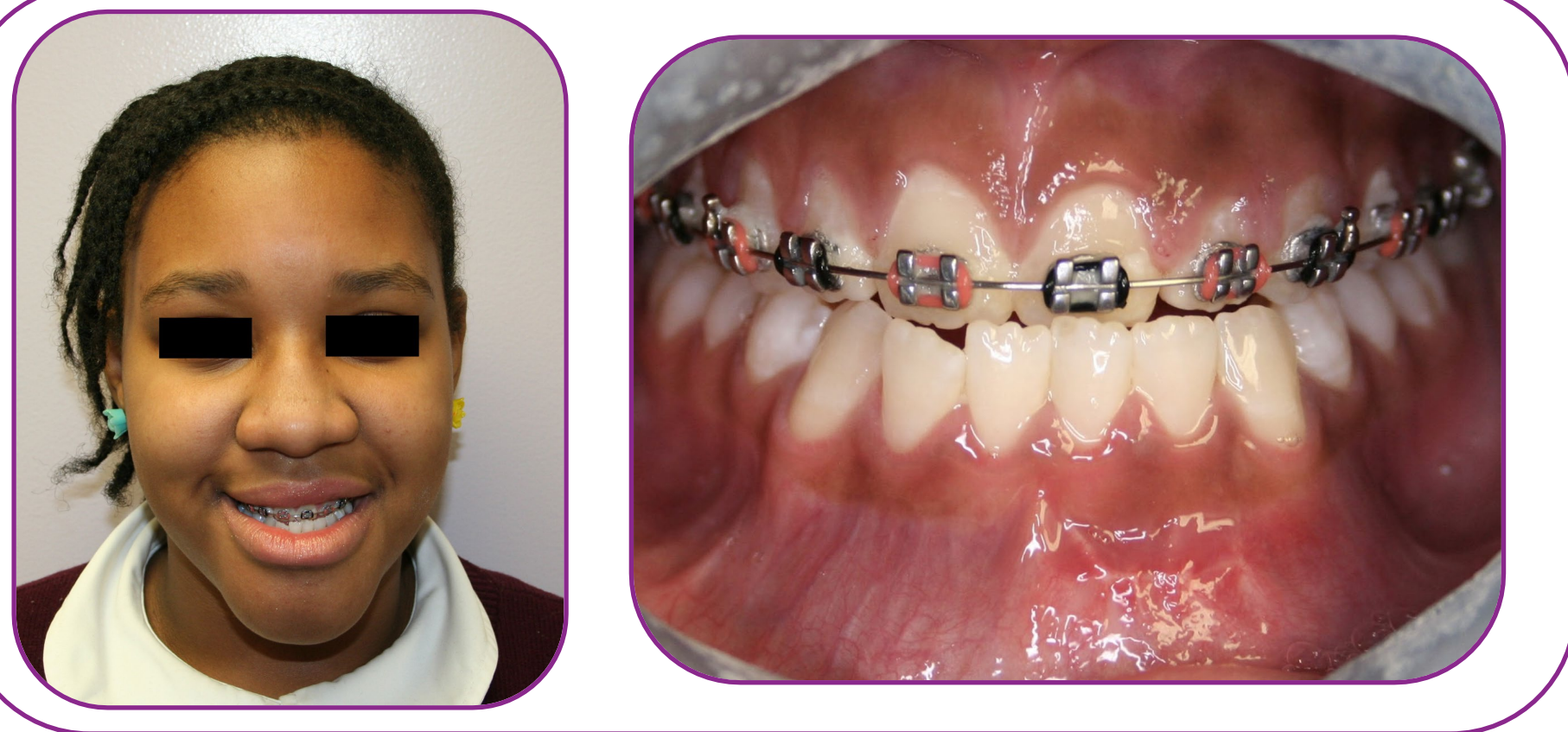## CASE

This is a case of a 12 year old female with a solid multicystic ameloblastoma in the anterior mandible extending from first premolar to first premolar. The patient was surgically planned for marginal resection with peripheral osteotomy and preservation of the inferior alveolar nerve and immediate reconstruction with posterior iliac crest graft. The patient was also planned for delayed placement of endosteal implants with a screw retained hybrid mandibular denture. Immediate temporization was achieved with RPD then transitioned to implant supported and retained removable prosthesis. The patient continued with yearly follow-ups, she is currently 10 years post-op with the initial final prosthesis.

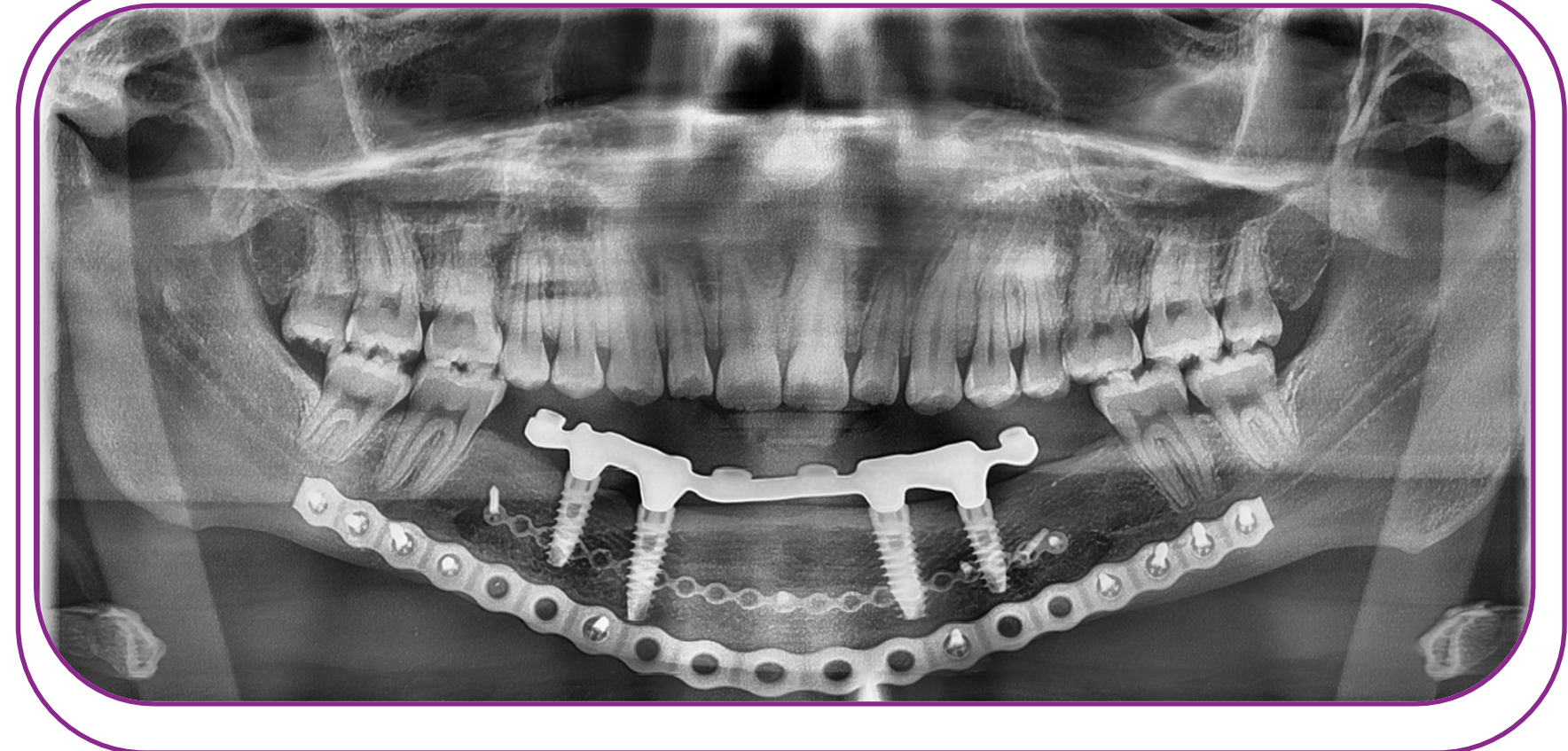
## PROSTHESIS



## 2010

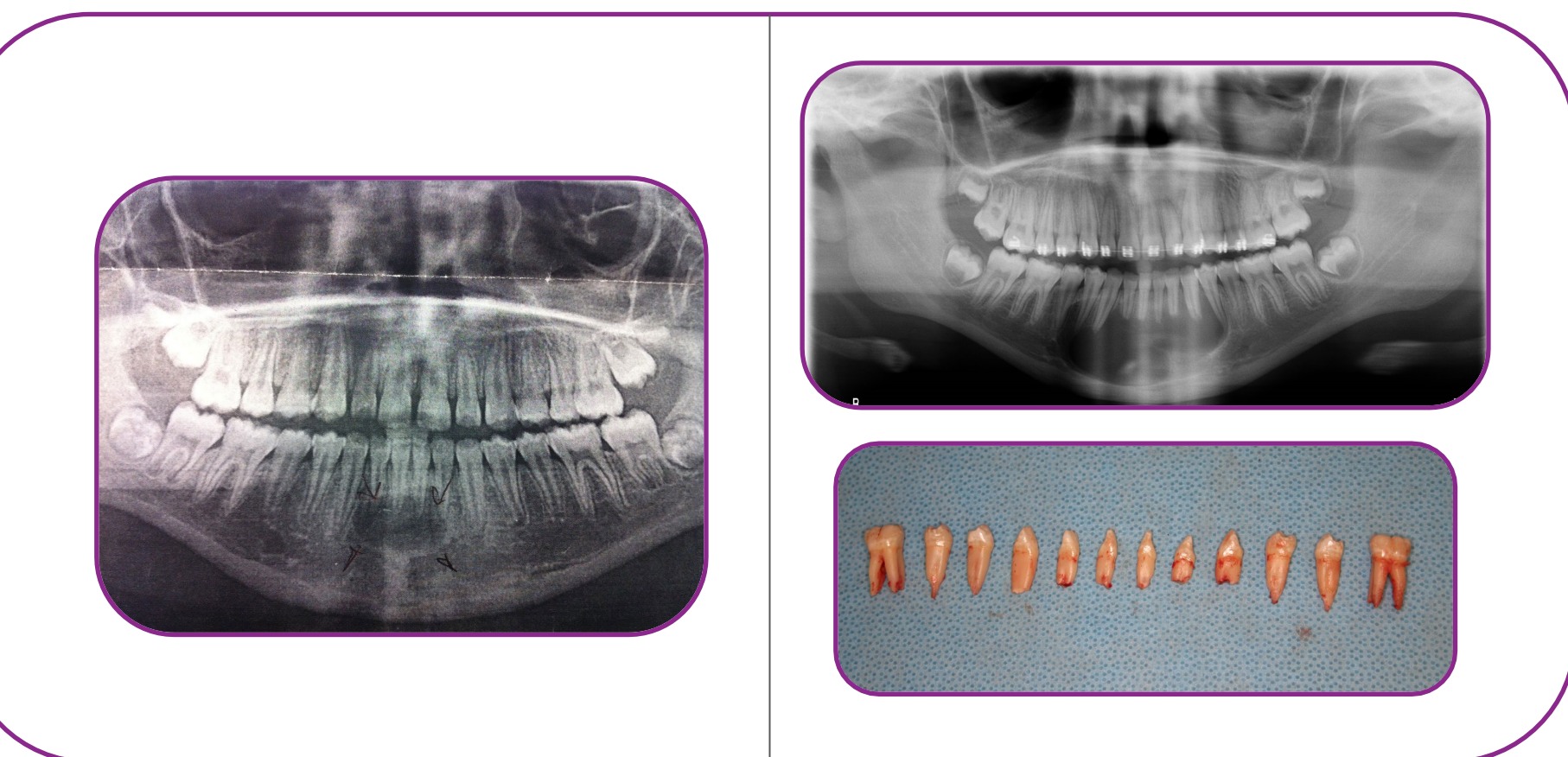


## 2023

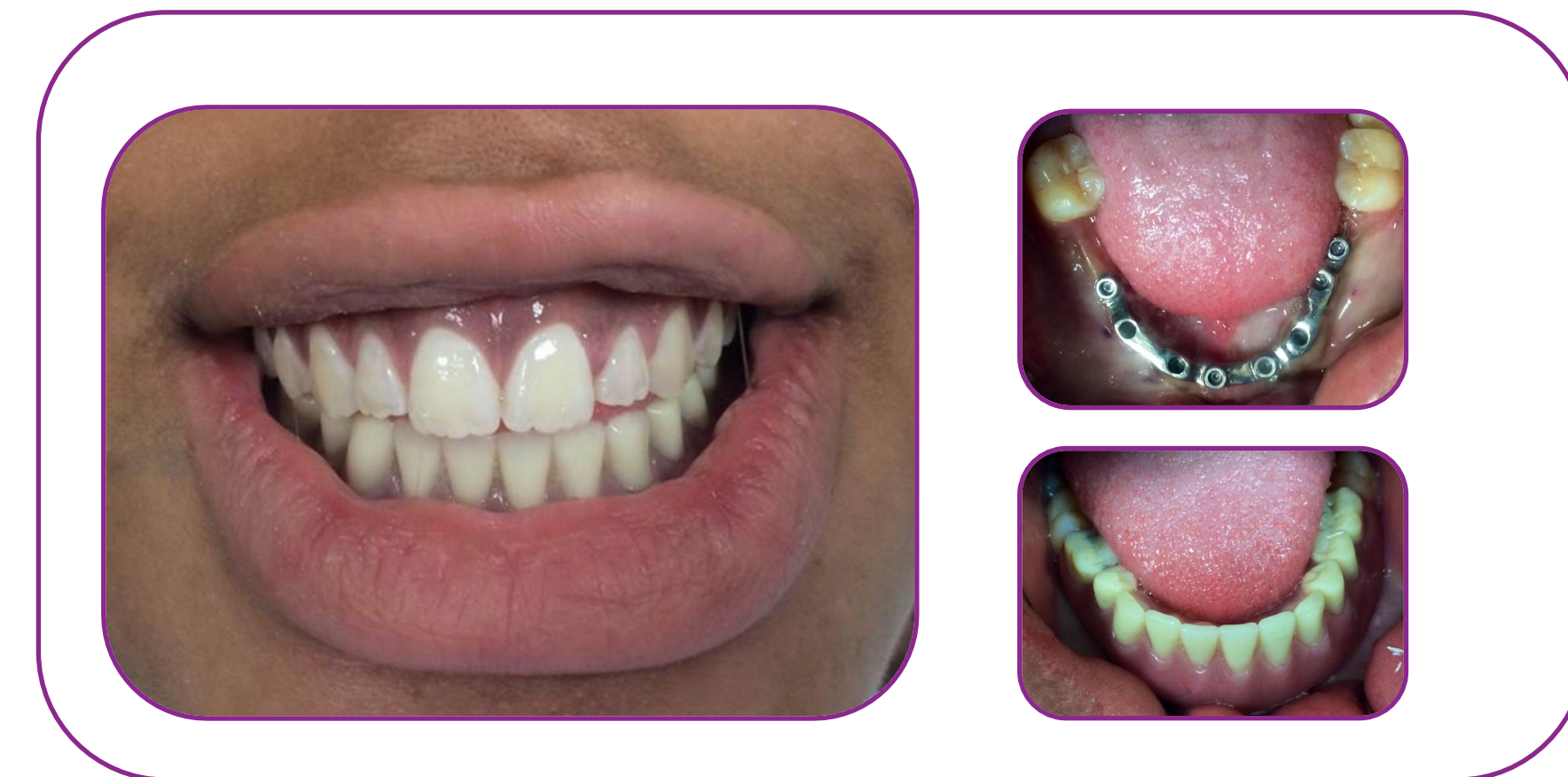


## 2010

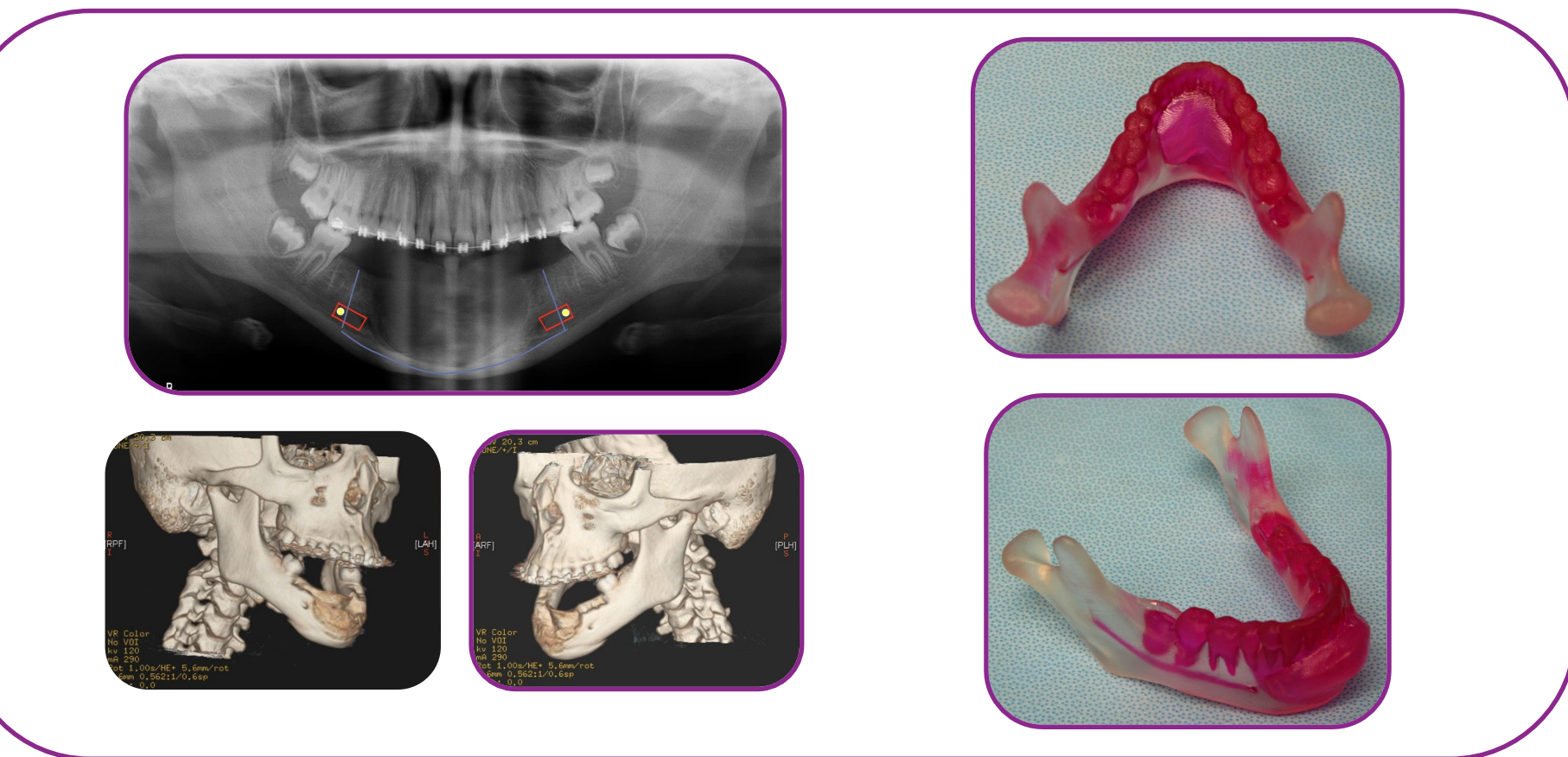
## 2012



## 2023



## SURGICAL PLANNING



## RESULTS/DISCUSSION

The patient is currently 10 years postoperative without pathologic recurrence. Full neurosensory recovery was initially noted. Complete consolidation of the graft and successful integration of four endosseous implants restored with bar suprastructure and overdenture was achieved. Patient and mother were pleased with esthetic result and function. Patient followed 6 month interval follow-ups and was then lost for 4 years and continued to follow yearly. Fixed prosthesis was recently offered to patient, though patient is content with current removable prosthesis. Patient will followed on a yearly basis moving forward

Pathologic entities in the pediatric population comprise a unique problem set which balance health, form, function, psychological and physical development. Prompt, aggressive, curative surgical intervention of pathology is the primary goal. Immediate reconstruction with dental implants and a hybrid prosthesis minimize the impact of the primary surgery while allowing future correction for growth through fabrication of a new denture. In this case the prosthesis was not needed in the sense of form, esthetics, or function. One would stipulate growth was stunted after her surgical procedure and the patients class III occlusion normalized with orthodontics. Nevertheless, one should consider growth patterns of the maxillofacial region when planning endosseous implants and prosthesis'.